

# Gastric Antral Vascular Ectasia (Watermelon Stomach)—An Enigmatic and Often-Overlooked Cause of Gastrointestinal Bleeding in the Elderly

Hien Nguyen, MD  
 Connie Le, MD  
 Hanh Nguyen, MD

## Abstract

Gastric antral vascular ectasia (GAVE) syndrome, also known as watermelon stomach is a significant cause of acute or chronic gastrointestinal blood loss in the elderly. It is characterized endoscopically by “watermelon stripes.” Without cirrhosis, patients are 71% female, average age 73, presenting with occult blood loss leading to transfusion-dependent chronic iron-deficiency anemia, severe acute upper gastrointestinal bleeding, and nondescript abdominal pain.

## Introduction

Gastric antral vascular ectasia (GAVE) syndrome, also known as watermelon stomach, is a rare but significant cause of severe acute or chronic gastrointestinal blood loss in the elderly.<sup>1-4</sup> Although it is associated with heterogeneous medical conditions, including hepatic, renal, and cardiac diseases, its pathogenesis is unknown.<sup>1-3</sup> The diagnosis of GAVE syndrome in patients with renal or hepatic disease is often problematic because there are more frequent causes of gastrointestinal bleeding in these diseases (vascular malformations, peptic ulcer disease, esophageal or gastric varices, and colonic and rectal ulcers) that overshadow GAVE syndrome. Furthermore, diagnosis may be challenging because gastrointestinal bleeding may be occult or overt, and the endoscopic appearance of GAVE syndrome resembles that in portal hypertensive gastropathy (PHG) or antral gastritis. However, differentiation of GAVE syndrome from these other causes is critical because of the vastly disparate therapies required for each. Building on a leading theory that mechanical stress is involved in the pathogenesis, we speculate that the diverse medical risk factors may be related to GAVE syndrome through an autonomic dysfunction.<sup>5,6</sup>

## Case Report

A woman, age 63 years, with a chronic hepatitis C infection, esophageal varices, and hemodialysis-dependent end-stage renal disease secondary to diabetes and hypertension presented at our institution and reported several weeks of intermittent generalized abdominal pain and vomiting and daily minimal stools that appeared blood-streaked on wiping but without hematemesis or melena. Laboratory findings showed a hemoglobin of 6.8 g/dL; a hematocrit of 20%; and normal hepatic function, platelet count, prothrombin time, and international normalized ratio. Although the anemia was consistent with iron deficiency, the low hemoglobin level invariably decreased to pretransfusion levels within days of blood transfusion. Contrast computed tomography scan of the abdomen revealed hepatomegaly but no other significant gastrointestinal pathology. Because our patient had had endoscopically proven portal esophageal varices and PHG two years before we examined her, which had been treated with sclerotherapy and propranolol, esophagogastroduodenoscopy was repeated in anticipation of further sclerotherapy for esophageal varices, PHG, or peptic ulcer disease.

Instead, a repeat endoscopy revealed extensive vascular ectasias and patchy erythema in the distal antrum that were diagnostic of GAVE syndrome, but no esophageal or gastric varices. A colonoscopy showed hemorrhoids. It was thought that hemorrhoidal bleeding alone could not explain the severe and relapsing anemia, and GAVE syndrome was considered a more plausible cause of severe anemia from gastrointestinal blood loss. The endoscopist considered primary medical therapy with laser photocoagulation but because of the presence of diffuse and advanced vascular ectasias did not believe that this would be sufficient and would

**Hien Nguyen, MD**, is an Internist at the Camp Springs Medical Center in Temple Hills, MD, and an Attending Internist at the Washington Hospital Center in Washington, DC. E-mail: hientrinhnguyen@yahoo.com.

**Connie Le, MD**, is an Attending Internist at the Fairfax Hospital in Fairfax, VA. E-mail: drconniele@aim.com.

**Hanh Nguyen, MD**, is a Resident at the University of California Irvine Medical Center in Irvine, CA. E-mail: hanhnguyenmd@gmail.com.

not produce long-lasting results. The patient was notified of the higher risks of definitive surgery in light of her multiple comorbidities and underwent an uncomplicated subtotal gastrectomy without a long-term need for blood transfusions.

## Discussion

Although GAVE syndrome is a rare medical condition, it is a relevant possibility in older patients with severe acute or chronic gastrointestinal blood loss, because it accounts for up to 4% of nonvariceal upper gastrointestinal blood loss.<sup>1-4,7</sup> The initial presentation may include occult blood loss leading to transfusion-dependent chronic iron-deficiency anemia, severe acute upper-gastrointestinal bleeding, nondescript abdominal pain, or even gastric outlet obstruction, as described in a prior case report. This disease entity was first described by Rider et al<sup>1</sup> in a patient with severe chronic iron-deficiency anemia and gastroscopy showing “fiery red changes with marked hypertrophic mucosal changes, and scattered profuse bleeding.”

A majority of patients without cirrhosis but with GAVE syndrome are female (71%) with median age of 73 years, whereas the majority of patients with both cirrhosis and GAVE syndrome are male (75%) with a mean age of 65 years.<sup>1,2</sup> Associated medical conditions include heart, liver, and kidney diseases; diabetes; connective-tissue diseases; hypothyroidism; and status as a bone marrow transplant recipient.<sup>1-4</sup> The epidemiologic features of GAVE syndrome are attributed to the age and sex distributions of the underlying medical conditions, of which connective-tissue diseases and cirrhosis are the most commonly related.<sup>1,2</sup>

The syndrome has the name *watermelon stomach* because of the pathognomonic endoscopic appearance (columns of red tortuous ectatic vessels along longitudinal folds of the antrum) that resembles watermelon stripes (Figure 1 and 2).<sup>1-5</sup> Typical histologic changes include superficial hyperplastic antral mucosa, capillary ectasia with thrombosis, and fibromuscular hypertrophy of the lamina propria.<sup>1-4</sup> GAVE syndrome is often misdiagnosed on endoscopy as PHG. Unlike watermelon stomach, PHG causes predominant changes in the fundus and corpus.<sup>1,2</sup> GAVE syndrome does not respond to measures that decrease portal pressures in PHG, including transjugular intrahepatic shunt and  $\beta$ -blocker therapy.<sup>1,2,4,7</sup>

Therapy for GAVE syndrome can be separated into three categories: pharmacologic, endoluminal, and surgical approaches.<sup>1,2,7-9</sup> Pharmacologic therapies have been described with the use of corticosteroids,

estrogen–progesterone combinations, tranexamic acid (with a significant risk of ischemic events and pulmonary emboli), thalidomide,  $\alpha$ -interferon, calcitonin, and cyproheptadine.<sup>1,2</sup> However, the effectiveness of all these medications have been described only in reports of single cases or small case series.<sup>1,2,7,8</sup> Endoluminal therapies are the mainstay of conservative management and include endoscopic band ligation, sclerotherapy, heater probe, and argon plasma coagulation, which is emerging as the preferred endoscopic therapy.<sup>1,2</sup> Although multiple intraluminal treatment sessions may be required for cessation of transfusion dependence, the safety of endoscopic therapy is well documented, and there is only a single case report of a complication—gastric outlet obstruction secondary to argon plasma coagulation.<sup>8</sup> Further, a recent case report described successful endoscopic mucosal resection of lesions in GAVE syndrome with resolution of anemia.<sup>9</sup>

There is a paucity of reports of controlled studies of GAVE syndrome in terms of medical versus surgical therapy. The consensus, however, is that primary surgical therapy is not advocated, because of reports of high morbidity and mortality from patients undergoing surgery with GAVE syndrome who often have multiple other serious medical comorbidities. However, Novitsky et al<sup>4</sup> have argued for a somewhat more aggressive surgical approach as second-line therapy, especially in patients in whom a short trial of endoluminal treatment fails. They argue that antrectomy is the only reliable therapy with definitive and curative potential, especially for unresponsive or severe disease. Minimally invasive laparoscopic antrectomy has also been advocated as a novel approach to the therapy of GAVE syndrome.<sup>10</sup> Furthermore, treatment of underlying medical conditions can lead to resolution of GAVE syndrome.<sup>1,2,4,7</sup> For instance, liver transplantation

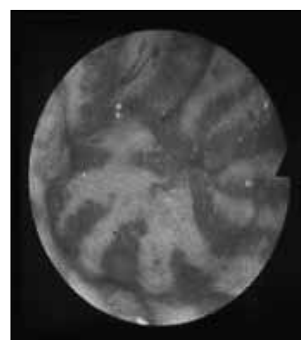


Figure 1. Endoscopic appearance of watermelon stomach.

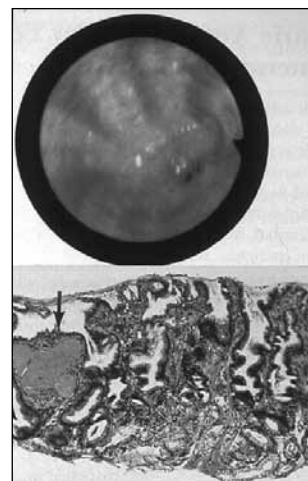


Figure 2. An alternate endoscopic appearance of watermelon stomach.

has been reported to lead to complete resolution of GAVE syndrome.<sup>1,2</sup>

Our case presentation demonstrates the therapeutic dilemmas in this problematic disease, whereas reports of controlled studies comparing efficacy are lacking. Our patient possessed multiple medical comorbidities that placed her at higher surgical risk. Thus, she was initially referred to an endoscopist for the purpose of conservative intraluminal therapy with argon plasma

**... disordered peristaltic waves may cause partial prolapse of distal gastric mucosa through the pylorus, leading to formation of ectatic vessels.<sup>5,6</sup>**

coagulation. However, the endoscopist concluded that the patient's particular mucosal lesions were so advanced and so diffuse that even intensive intraluminal therapy would be inadequate and would surely result in the need for multiple therapies that would produce questionable long-term control. This was significant because the patient had a history of lack of compliance, including regarding taking medications and keeping appointments for multiple medical evaluations across different specialties. The patient

was advised about the risks and benefits of intraluminal versus surgical therapy, the latter of which the surgeon believed offered a more conclusive and definitive cure; the outcome was favorable.

The pathogenesis of GAVE syndrome, principally considered an idiopathic disease, is unknown, and theories about it are controversial.<sup>1,2</sup> An understanding of the pathophysiologic changes that lead to GAVE syndrome is lacking because most theories are based on single case reports or on reports of smaller series of fewer than 15 cases. However, a leading and plausible theory suggests antropyloric motility dysfunction.<sup>6</sup> Quintero et al<sup>5</sup> first conceptualized a theory of mechanical stress, where disordered peristaltic waves may cause partial prolapse of distal gastric mucosa through the pylorus, leading to formation of ectatic vessels.<sup>6</sup> This disordered peristalsis and loss of gastric propulsive activity and motility may occur secondary to denervation of the digestive autonomic nervous system, which is primarily parasympathetic.<sup>6</sup> The characteristic histologic finding of fibromuscular hyperplasia in GAVE syndrome further supports this hypothesis.<sup>1-6</sup>

We speculate that the altered gastric and antral motility in some patients with GAVE syndrome may be modulated by vagal denervation and sympathetic overactivity, which are already known to exist in many of the associated medical problems.<sup>5,6</sup> Chronic liver disease is known to impair cardiovascular autonomic reflexes, whereas sympathetic overactivity is implicated in the pathogenesis and progression of renal diseases

and heart failure.<sup>11-13</sup> For several decades, it has been known that plasma norepinephrine levels are elevated in chronic renal failure, indicative of increased sympathetic nerve activity.<sup>12</sup> Interestingly, recent research has hypothesized a role for the sympathetic nervous system in the modulation and expression of autoimmune lymphoproliferative and connective-tissue diseases such as systemic lupus erythematosus.<sup>14</sup> Thus, these diverse medical conditions may share a common autonomic dysfunction with GAVE syndrome.<sup>12-14</sup> In a retrospective chart review of our patient, we discovered that she had multiple symptoms suggestive of autonomic neuropathy and dysfunction, including neuropathy of the lower extremities, orthostatic hypotension, frequent hypoglycemia, and gastroparesis.

## Conclusion

GAVE syndrome is an important diagnosis to consider in older patients with severe anemia and occult or profuse gastrointestinal bleeding, especially in the setting of heart, liver, or kidney diseases.<sup>1-4</sup> The main inherent teaching point is that GAVE syndrome can be inadvertently overlooked as a remediable cause of gastrointestinal bleeding because there are more frequent causes of gastrointestinal bleeding (esophageal or gastric varices, PHG, and peptic ulcer disease) among patients with renal or hepatic diseases, which are the same medical conditions in which GAVE syndrome occurs. The endoscopic appearance of GAVE syndrome often mimics that of PHG or antral gastritis. Further, the case we reported here demonstrates that GAVE syndrome may be underdiagnosed because observational studies of screening gastroscopies in patients undergoing liver transplantation show that 1 in 40 patients has GAVE syndrome.<sup>1,2</sup> Because this is a single-case report, we speculate that in larger case series, further studies of neurohormonal factors that may be involved in sympathetic nervous system dysfunction and disordered peristalsis in GAVE syndrome may provide more insight into the pathogenesis of this enigmatic disease.<sup>11-14</sup> ❖

## Disclosure Statement

*The author(s) have no conflicts of interest to disclose.*

## Acknowledgments

*The authors would like to thank the Scleroderma Program, Division of Rheumatology, University of Michigan Medical Center for Figure 1 and the Pathology Department, University of Pittsburgh Medical Center for Figure 2.*

*Katharine O'Moore-Klopf, ELS, of KOK Edit provided editorial assistance.*

---

**References**

1. Rider JA, Klotz AP, Kirshner JB. Gastritis with veno-capillary ectasia as a source of massive gastric hemorrhage. *Gastroenterology* 1953 May;24(1):118-23.
2. Selinger CP, Ang YS. Gastric antral vascular ectasia (GAVE): an update on clinical presentation, pathophysiology and treatment. *Digestion* 2008;77(2):131-7.
3. Stefanidis I, Liakopoulos V, Kapsoritakis AN, et al. Gastric antral vascular ectasia (watermelon stomach) in patients with ESRD. *Am J Kidney Dis* 2006 Jun;47(6):e77-82.
4. Novitsky YW, Kercher KW, Czerniach DR, Litwin DE. Watermelon stomach: pathophysiology, diagnosis, and management. *J Gastrointest Surg* 2003 Jul-Aug;7(5):652-61.
5. Quintero E, Pique JM, Bombi JA, et al. Gastric mucosal vascular ectasias causing bleeding in cirrhosis. A distinct entity associated with hypergastrinemia and low serum levels of pepsinogen I. *Gastroenterology* 1987 Nov;93(5):1054-61.
6. Charneau J, Petit R, Calès P, Dauver A, Boyer J. Antral motility in patients with cirrhosis with or without gastric antral vascular ectasias. *Gut* 1995 Oct;37(4):488-92.
7. Dulai GS, Jensen DM, Kovacs TO, Gralnek IM, Jutabha R. Endoscopic treatment outcomes in watermelon stomach patients with and without portal hypertension. *Endoscopy* 2004 Jan;36(1):68-72.
8. Farooq FT, Wong RC, Yang P, Post AB. Gastric outlet obstruction as a complication of argon plasma coagulation for watermelon stomach. *Gastrointest Endosc* 2007 Jun;65(7):1090-2.
9. Kastsinelos P, Chatzimavroudis G, Katsinelos T, et al. Endoscopic mucosal resection for recurrent gastric antral vascular ectasia. *Vasa* 2008 Aug;37(3):289-92.
10. Sherman V, Klassen DR, Feldman LS, Jabbari M, Marcus V, Fried GM. Laparoscopic antrectomy: a novel approach to treating watermelon stomach. *J Am Coll Surg* 2003 Nov;197(5):864-7.
11. Stadlbauer V, Wright GA, Banaji M, et al. Relationship between activation of the sympathetic nervous system and renal blood flow autoregulation in cirrhosis. *Gastroenterology* 2008 Jan;134(1):111-19. Erratum in: *Gastroenterology* 2008 Mar;134(3):897. Stadlbauer V, Mookerjee RP.
12. Vonend O, Rump LC, Ritz E. Sympathetic overactivity—the Cinderella of cardiovascular risk factors in dialysis patients. *Semin Dial* 2008 Jul-Aug;21(4):326-30.
13. Goldsmith SR. Interactions between the sympathetic nervous system and the RAAS in heart failure. *Curr Heart Fail Rep* 2004 Jul;1(2):45-50.
14. del Rey A, Besedovsky HO. Sympathetic nervous system-immune interactions in autoimmune lymphoproliferative diseases. *Neuroimmunomodulation* 2008;15(1):29-36.

---

### No Bagel

When dealing with an intra-abdominal problem  
the clinician's greatest ally is the radiologist.  
As a matter of fact, gastroenterology without  
expert radiology is like lox without a bagel.

— *Gerald S Foster, 1977*