

REVIEW ARTICLE

# Natural Orifice Transluminal Endoscopic Surgery: The Future of Gastrointestinal Surgery

Lee L Swanström, MD, FACS  
 Yashodan Khajanchee, MD  
 Maher A Abbas, MD,  
 FACS, FASCRS

## Introduction

Considering the continued evolution of flexible endoscopy into more of a therapeutic tool and, at the same time, the growing awareness that the degree of invasiveness of surgery has a large impact on patient outcomes, it was perhaps inevitable that endoscopy and surgery would eventually work together (Figure 1). Accelerating technologic developments mean that this theoretic point of fusion has a potential clinical ap-

plausibility. laparoscopic procedures over conventional laparotomy in terms of patient recovery and perioperative morbidity, the increasing skill set of advanced laparoscopists, and the comfort of practitioners in performing complex surgeries using video imaging and pneumoperitoneum raised the possibility of replicating such operations endoscopically. The first report of oral peritoneoscopy done in animals was published by Kalloo et al<sup>3</sup> in 2004. Since then, multiple investigators have used transluminal flexible endoscopy in animal models to perform various intraperitoneal procedures, ranging from tubal ligation to splenectomy<sup>3-8</sup> (Table 1). There have been additional reports of clinical cases, but no publications about them have appeared. On the basis of these initial reports exploring both the scope and

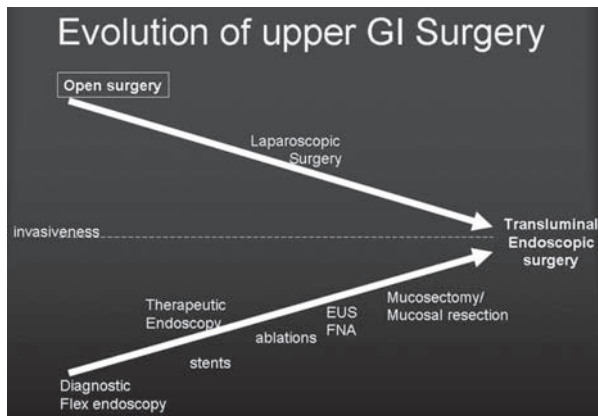


Figure 1. Merging of surgery and therapeutic endoscopy

plication. It is conceivable that the current generation of surgical endoscopists is on the verge of witnessing a true paradigm shift, which is being referred to as Natural Orifice Transluminal Endoscopic Surgery (NOTES). The potential of flexible endoscopy to perform therapeutic procedures beyond the wall of the gastrointestinal tract was recognized as early as 1980 when the first transluminal feeding gastrostomy was described by Gauderer et al.<sup>1</sup> Kozarek et al<sup>2</sup> published the first report of successful endoscopic drainage of pseudocyst in 1985. On the surgical side, the established benefits of

Table 1. NOTES procedures described to date

Laboratory reports	Cholecystectomy
	Splenectomy
	Tubal ligation
	Gastrojejunostomy
	Pyloroplasty
	Staging peritoneoscopy
	Liver biopsy
	Diaphragm pacing
	Distal pancreatectomy
	Ventral hernia repair
	Gastric sleeve resection
	Colectomy (right and left)
Human cases	Transgastric appendectomy
	Transvaginal cholecystectomy
	Transgastric cholecystectomy
	Percutaneous enteral gastrostomy salvage
	Cancer staging

NOTES = natural orifice transluminal endoscopic surgery.



**Lee L Swanström, MD, FACS**, (top) is the Director of the Minimally Invasive Surgery Division, Legacy Health System, and a Clinical Professor of Surgery at Oregon Health Sciences University in Portland, OR. E-mail: lswanstrom@aol.com.  
**Yashodan Khajanchee, MD**, (left) is a Surgeon in the Minimally Invasive Surgery Division, Legacy Health System, and a Researcher in the Department of Research at Oregon Health Sciences University in Portland, OR. E-mail: yashodhansk@yahoo.com.  
**Maher A Abbas, MD, FACS, FASCRS**, (right) is an Assistant Clinical Professor of Surgery at UCLA; the Chief of Colon and Rectal Surgery, Department of Surgery at the Los Angeles Medical Center. E-mail: maher.a.abbas@kp.org.

feasibility of NOTES, the transluminal approach appears to have tremendous potential. However, several important issues, including the safety of this approach and whether it will provide significant patient benefit in terms of postoperative recovery compared with laparoscopy, must be resolved before the new technique is widely introduced into clinical use. Additionally, it is recognized that early use of this approach by surgeons or gastroenterologists who might be relatively inexperienced in the particular skill sets required might lead to serious complications, which should definitely be avoided during the infancy of this concept. To head off such errors and to develop NOTES in a responsible and safe manner, a working group of 14 leading laparoscopic surgeons and endoscopists from the Society of American Gastrointestinal Endoscopic Surgeons (SAGES) and the American Society for Gastrointestinal Endoscopy (ASGE) met in July 2005. The working group was named Natural Orifice Surgery Consortium for Assessment and Research (NOSCAR). The prime goal of the meeting was to produce a document that would serve as a guide for responsible development of NOTES. In the white paper that the group subsequently published, NOSCAR discussed in detail the potential challenges to safe use of NOTES in clinical practice and outlined guidelines for investigators working on NOTES and criteria for expanding participation in NOSCAR.<sup>9</sup>

### Will Natural Orifice Transluminal Endoscopic Surgery Offer Advantages Over Current Surgical Techniques?

When the laparoscopic approach was introduced, it was initially argued that it might not provide any benefit to the patient other than better cosmesis. Since then, multiple benefits of laparoscopic surgery, including a decreased neurohumoral stress response,<sup>10</sup> decreased immunosuppression,<sup>11</sup> less pain, faster recovery,<sup>12</sup> and a decreased incidence of wound-related and pulmonary complications, have been recognized.<sup>13</sup> In spite of initial skepticism then, today laparoscopy has become a standard approach for most general surgical, gynecologic, and urologic procedures and has been widely accepted for several oncologic procedures as well. NOTES should provide all of the above-mentioned advantages of laparoscopic surgery. In addition, the elimination of all abdominal wall incisions might have several potential benefits. Wound infection is a common surgical complication, with a reported incidence ranging between 2% and 25%, depending on the type of surgery performed.<sup>14,15</sup> This has a tremendous adverse impact on patient recovery and

health care costs.<sup>16</sup> Eliminating all skin incisions would completely eliminate this risk. Incisional hernias and increasing rates of postoperative adhesions are thought to correlate with the size of abdominal wall incision. The incidence of incisional hernia is substantially lower with laparoscopic procedures, where incision size is much smaller than for open surgery, and should be eliminated with NOTES (4%–18% with open surgery<sup>17–19</sup> vs 0.2%–3% with laparoscopic surgery<sup>20</sup>). Similarly, the reported rates of small-bowel obstruction due to adhesions are also significantly lower after laparoscopic surgery compared with open surgery (3.3% vs 7.7%) and will perhaps be further decreased with NOTES.<sup>21</sup> Reducing or eliminating these complications would be an important improvement in patient care as well as a major cost savings to society as a whole. Other potential benefits that NOTES has been theorized to offer are decreased postoperative pain, less need for postoperative analgesia, shorter hospital stay, and faster recovery. Additionally, NOTES may have several advantages in specific subpopulations. It may provide an easy alternative access to the peritoneal cavity in morbidly obese patients, in whom traditional open or laparoscopic access can be difficult because of abdominal wall thickness, and could possibly reduce the lifetime risk of incision-related complications in children.<sup>22</sup>

**Table 2. Potential challenges to clinical application of NOTES**

Peritoneal access
Gastric closure
Prevention of infection
Suturing and anastomosing devices
Spatial orientation
Developing a multitasking platform
Management of complications
Understanding untoward physiologic consequences
Training

NOTES = natural orifice transluminal endoscopic surgery.

### Current Challenges

Although NOTES appears to offer definite patient benefits, several critical issues must be resolved before it can be successfully and responsibly used in clinical care. NOSCAR has identified several potential challenges to safe introduction of NOTES<sup>9</sup> (Table 2). Although the relative importance of these challenges is debatable, there is unanimous consensus among experts regarding the critical nature of the need for secure enterotomy closure, understanding the physiologic consequences of NOTES, and the need for adequate training. In the vari-

**Table 3. Guidelines for participating in NOSCART**

Must have a multidisciplinary team that possesses both advanced flexible endoscopic skills and laparoscopic skills
Should be a member of SAGES and/or ASGE
Must have animal laboratory facilities in which to perform research and training
Must agree to share laboratory results with other NOSCART members at semiannual meetings
Must agree that all human procedures be performed only after obtaining approval from an institutional review board or an equivalent body
Must submit all cases to an outcomes registry that will be maintained by sponsoring societies

ASGE = American Society for Gastrointestinal Endoscopy; NOSCART = Natural Orifice Surgery Consortium for Assessment and Research; SAGES = Society of American Gastrointestinal Endoscopic Surgeons.

ous animal experiments, several different techniques, such as suturing, clips, T-fasteners, and novel closure devices, have been employed by different investigators to obtain a secure closure of the enterotomy. It is very important that the closure device and the technique be easy to use and provide a nearly 100% secure closure of the enterotomy site. Complications of enterotomy leakage will create a big hurdle to the safe clinical use of NOTES. It is widely accepted that given the safety of laparoscopic approach, an enterotomy leak rate of even 1% would be unacceptable.

The physiologic consequences of pneumoperitoneum for various organ systems have been extensively studied in laparoscopic surgery. However, it is not known whether the pneumoperitoneum created during NOTES will behave in the same fashion. Initial reports suggest difficulties maintaining a controlled pressure or required flow rates through flexible endoscopes. Investigators have reported difficulties in maintaining tight seals around the enterotomy that can effectively prevent backflow of carbon dioxide into the stomach. Additionally, leakage of gas into the gastrointestinal tract can lead to loss of domain within the peritoneal cavity. Finally, there is the danger inherent in using current flexible endoscopic insufflators, which are not pressure regulated. These technologic hurdles must be resolved before NOTES can be successfully used in clinical practice.

A third, and perhaps the most important, challenge for safe clinical use of NOTES will be the development of effective training programs and credentialing guidelines. Because NOTES requires surgeons to be adept in both minimally invasive surgery as well as advanced flexible endoscopy and therefore may involve both surgeons and gastroenterologists, multidisciplinary training programs will be necessary. NOSCART has taken an initial step to expand participation of investiga-

tors interested in or already working on NOTES from around the globe and have outlined criteria for who can participate (Table 3). Eventually, as the safety and efficacy of NOTES are established for various procedures, guidelines for training and credentialing can be developed.

### Current Technologic Developments

Currently available flexible endoscopes are inadequate for performing complex transluminal surgical procedures. Issues with current flexible scopes include the lack of a multitasking platform, the number and size of access channels, the inability to position and then fix or "stiffen" the endoscope to allow robust retraction and exposure, the inability to control insufflation pressures, fixed visual horizons that force the surgeon to adjust to tilted or inverted views, and inadequate suction/irrigation capabilities. These problems can be resolved to some extent with scope-handling expertise and by altering the surgical approach. However, a better long-term solution will be to redesign the endoscopic access device itself. Several prototype endoscopes are being tested, including the Transport and Cobra (USGI Medical, San Juan Capistrano, CA), the R scope (Olympus, Center Valley, PA), and the robotic Endovia (Hansen Medical, Mountain View, CA), all designed to resolve these issues. The Trans-

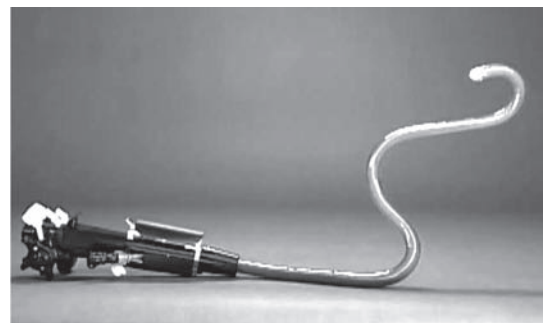


Figure 2. The Transport advanced operating endoscope [USGI Medical, San Juan Capistrano, California].




Figure 3. The Cobra triangulating scope [USGI Medical, San Juan Capistrano, California].

port and Cobra devices adapted an existing design of a locking overtube (ShapeLock, USGI Medical), adding independent steering of the tip, four channels and an insufflator connection. The Transport (Figure 2) is a 16-mm flexible device with four large channels. One of the channels is designed for a standard 6-mm flexible endoscope, which can be locked into position but also can be torqued independently to correct the horizon. The Transport is capable of 180° retroflexion as well as lateral movements and can be frozen in place by closing a lever, whereas the tip still has independent four-way movement for fine surgical maneuvers. It also provides connection to a standard laparoscopic insufflator for an effective, controlled carbon dioxide pneumoperitoneum. The large 4- and 6-mm channels allow passage of the new stronger and flexible surgical tools. The Cobra and Endovia devices both are designed to provide triangulation, thought by many surgeons to be an essential feature (Figure 3). The R scope (Figure 4) is a traditional-size scope with an extra flexion point to better position the tip and with two access channels (3.8 mm) with horizontal and vertical lifters, which offer a reasonable simulation of triangulation. There is also a need to design more aggressive instrumentation. At present only a limited number of flexible endoscopic instruments are available. Owing to the small channel size of currently available endoscopes, the end effectors of most of these instruments are small and feeble. This makes tissue grasping and manipulation challenging. Ideally, instruments for flexible endoscopic surgery should replicate the designs of laparoscopic instruments to permit true surgeries. The newer prototype scopes (Figure 5), which have large working channels and are being tested, have allowed the creation of 4.5-mm graspers with 2.5-cm jaws that are similar to laparoscopic tools. There is need for further development of improved energy sources for dissection and hemostasis in a flexible format, including some that would be an alternative to bipolar circumactive probe cautery, the needle knife, and the sphincterotome. Of primary importance is the need for easy-to-use tissue approximation devices that can provide secure full-thickness closures of inadvertent perforations or intentional enterotomies, as well as anastomosis and bleeding control. Many devices designed to achieve these goals and to enable the use of NOTES are in development<sup>23</sup>. The Eagle Claw (Olympus) and the Swain closure system (Ethicon, Cincinnati, OH) seem to answer many of these requirements and are nearing commercial readiness.<sup>24</sup> The Eagle Claw (Figure 6),

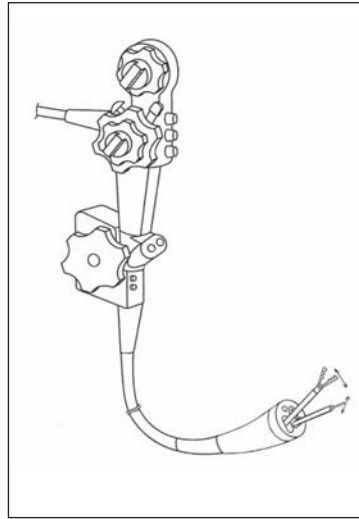


Figure 4. (left) The Olympus R [Olympus, Center Valley, Pennsylvania] is a commercially available dual channel operating scope.



Figure 5. (right, upper) More robust flexible instruments will allow surgery to be performed endoscopically.



Figure 6. (right, lower) The Eagle Claw [Olympus, Center Valley, Pennsylvania] suturing device with a semi-circular needle.

developed in collaboration between the Apollo Group<sup>a</sup> and Olympus, is a simple grasping and needle-driving device that fits on the end of a standard endoscope. It is capable of grasping large amounts of tissue and taking substantial bites with the needle. The needle delivers a pretied monofilament suture with a sliding lock that can be cinched down with a separate device. The Swain system (Figure 7) has two T-fasteners attached together with a sliding lock on the connecting suture. This system is flexible and easy to apply but has been associated with risk of injury to adjacent structures because the extramural deployment is blind. The g-Prox Tissue Grasper from USGI Medical allows the surgeon to grasp a full-thickness bite of tissue and then perforate it perpendicularly with a 19-gauge needle. The needle is preloaded with a suture with two expandable baskets. The first basket is expelled on one side of the grasped tissue, which is then released, allowing the grasper to either be reversed for a figure-of-eight suture or used again the same way for a simple stitch. The second bite is pierced again with the needle and the second basket is deployed. A one-way cinching device approximates the two baskets, creating a tight, imbricated closure of the enterotomy edges (Figure 8). In our laboratory, this device has achieved closure of gastrostomies as securely as hand sutures.<sup>25</sup>

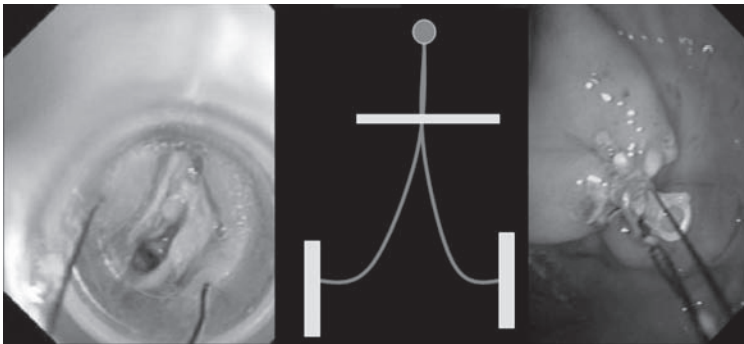


Figure 7. The Swain closure system [Ethicon, Cincinnati, Ohio] uses a pair of T-tags and a sliding cinch for full thickness closure.

### Potential Impact of Natural Orifice Transluminal Endoscopic Surgery on Health Care Systems

The mission of Kaiser Permanente (KP) is to provide high-quality, affordable health care services to improve the health of its members and the communities it serves. To achieve this mission, KP strives to raise the standard of care through promotion of best practices and integration of new beneficial technology. Teamwork, collaboration, and a multidisciplinary approach to the care of the patient are hallmarks of the KP practice. What impact might NOTES have on the practice of medicine and health care systems such as KP in the 21st century? Undoubtedly the technology and data needed to support the practice of NOTES will continue to evolve, driven by innovation, a rapid growth in animal experimentation, and human clinical trials to investigate the benefits, physiologic impact, complications, safety, cost, widespread feasibility, training, and long-term outcome of NOTES. This new experimental field may,

in the near future, establish itself as a viable alternative to open and laparoscopic surgery for the treatment of many gastrointestinal and abdominal conditions. When and if this occurs, the implementation of NOTES will have numerous ramifications at several levels, including those of the patient, health care systems, insurance companies, state and national governments, legislative organizations, and professional societies.

Recognizing the benefits and advantages of laparoscopic surgery, KP was one of the first large health care organizations to adopt minimally invasive procedures in the fields of gastrointestinal, gynecologic, and urologic surgery. Because of its large patient population, integrated multidisciplinary practice, and a high degree of subspecialization within its ranks, KP can potentially play an important role in the evolution and growth of NOTES procedures. In addition to the potential benefits to the patient, NOTES can positively affect the organization as a whole. KP physicians will remain at the forefront of clinical medicine. Although the cost-effectiveness of NOTES is yet to be demonstrated, it is conceivable that it might yield significant cost savings by shifting some inpatient care to the outpatient setting, decreasing pharmacy cost, and reducing the cost of care related to short- and long-term postoperative complications (ie, wound infection, intestinal obstructions, and hernia). The practice of some surgical fields might be redefined, with a potential restructuring of the complex and expensive traditional operating-room settings and relocation of a new generation of interventional procedures to less costly therapeutic and interventional endoscopy suites.

### Conclusions

Surgery is evolving beyond current flexible endoscopic and laparoscopic approaches. NOTES may represent the next phase of minimally invasive surgery, and early clinical experience shows that intra-abdominal surgery using flexible endoscopes is indeed possible. Because of the immaturity of the instrumentation, early cases demand a technical virtuosity that probably precludes a widespread application of this approach. This balance will shift as enabling technologies are developed. Nevertheless, NOTES will always be more technically demanding than open or laparoscopic surgery. If definite patient benefits are documented, if the public begins to demand “incisionless” surgery, or if both are the case, practitioners will need to master these techniques. Yet to be resolved is who will perform NOTES—gastroenterologists or surgeons versus a new breed of surgical endosco-

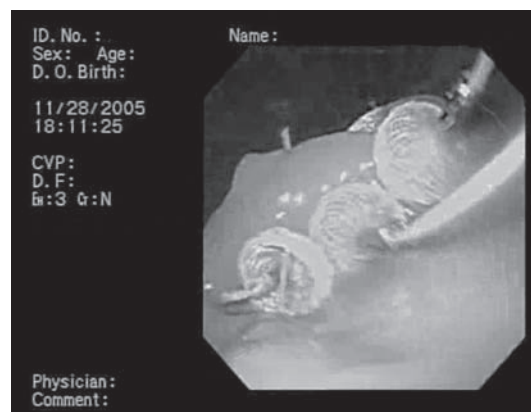


Figure 8. Closure of a NOTES gastrotomy using the g-prox system [USGI Medical, San Juan Capistrano, California].

pists. The answer will depend on which procedures are shown to merit a NOTES approach (high-volume “bread and butter” procedures or esoteric tertiary-center procedures), as well as on how issues such as credentialing and malpractice are resolved. ❖

<sup>a</sup> The Apollo Group is an international group of investigators whose goal is to develop new endoscopic technologies to successfully perform extragastric endoscopic surgeries.

#### Disclosure Statement

*Dr Swanstrom discloses that he is a consultant for USGI and Boston Scientific and that he receives research funding from USGI Medical and Olympus. The coauthors have no conflicts of interest to disclose.*

#### Acknowledgment

*Katharine O'Moore-Klopf of KOK Edit provided editorial assistance.*

#### References

- Gauderer MW, Ponsky JL, Izant RJ Jr. Gastrostomy without laparotomy: a percutaneous endoscopic technique. *J Pediatr Surg* 1980 Dec;15(6):872–5.
- Kozarek RA, Brayko CM, Harlan J, Sanowski RA, Cintora I, Kovac A. Endoscopic drainage of pancreatic pseudocysts. *Gastrointest Endosc* 1985 Oct;31(5):322–7.
- Kaloo AN, Singh VK, Jagannath SB, et al. Flexible transgastric peritoneoscopy: a novel approach to diagnostic and therapeutic interventions in the peritoneal cavity. *Gastrointest Endosc* 2004 Jul;60(1):114–7.
- Wagh MS, Merrifield BF, Thompson CC. Endoscopic transgastric abdominal exploration and organ resection: initial experience in a porcine model. *Clin Gastroenterol Hepatol* 2005 Sep;3(9):892–6.
- Park PO, Bergström M, Ikeda K, Fritscher-Ravens A, Swain P. Experimental studies of transgastric gallbladder surgery: cholecystectomy and cholecystogastric anastomosis (videos). *Gastrointest Endosc* 2005 Apr;61(4):601–6.
- Bergström M, Ikeda K, Swain P, Park PO. Transgastric anastomosis by using flexible endoscopy in a porcine model. *Gastrointest Endosc* 2006 Feb;63(2):307–12.
- Jagannath SB, Kantsevov SV, Vaughn CA, et al. Peroral transgastric endoscopic ligation of fallopian tubes with long-term survival in a porcine model. *Gastrointest Endosc* 2005 Mar;61(3):449–53.
- Kantsevov SV, Hu B, Jagannath SB, et al. Transgastric endoscopic splenectomy: is it possible? *Surg Endosc* 2006 Mar;20(3):522–5.
- Rattner D, Kaloo A, Brugge W, et al. ASGE/SAGES Working Group on Natural Orifice Transluminal Endoscopic Surgery. *Gastrointest Endosc* 2006 Feb;20(2):329–33.
- Karayianakis AJ, Makri GG, Mantzioka A, Karousos D, Karatzas G. Systemic stress response after laparoscopic or open cholecystectomy: a randomized trial. *Br J Surg* 1997 Apr;84(4):467–71.
- Burpee SE, Kurian M, Murakame Y, Benevides S, Gagner M. The metabolic and immune response to laparoscopic versus open liver resection. *Surg Endosc* 2002 Jun;16(6):899–904.
- Hardy KJ, Miller H, Fletcher DR, Jones RM, Shulkes A, McNeil JJ. An evaluation of laparoscopic versus open cholecystectomy. *Med J Aust* 1994 Jan 17;160(2):58–62.
- Hasuki S, Mesi D, Dizdarevi E, Keser D, Hadziselimovi S, Bazardzanovi M. Pulmonary function after laparoscopic and open cholecystectomy. *Surg Endosc* 2002 Jan;16(1):163–5.
- Bratzler DW, Houck PM. Antimicrobial prophylaxis for surgery: an advisory statement from the National Surgical Infection Prevention Project. *Clin Infect Dis* 2004 Jun 15;38(12):1706–15.
- DiPiro JT, Martindale RG, Bakst A, Vacani PF, Watson P, Miller MT. Infection in surgical patients: effects on mortality, hospitalization, and postdischarge care. *Am J Health Syst Pharm* 1998 Apr 15;55(8):777–81.
- Kirkland KB, Briggs JP, Trivette SL, Wilkinson WE, Sexton DJ. The impact of surgical-site infections in the 1990s: attributable mortality, excess length of hospitalization, and extra costs. *Infect Control Hosp Epidemiol* 1999 Nov;20(11):725–30.
- Mingoli A, Puggioni A, Sgarzini G, et al. Incidence of incisional hernia following emergency abdominal surgery. *Ital J Gastroenterol Hepatol* 1999 Aug–Sep;31(6):449–53.
- O'Dwyer PJ, Courtney CA. Factors involved in abdominal wall closure and subsequent incisional hernia. *Surgeon* 2003 Feb;1(1):17–22.
- Carlson MA, Ludwig KA, Condon RE. Ventral hernia and other complications of 1000 midline incisions. *South Med J* 1995 Apr;88(4):450–3.
- Montz FJ, Holschneider CH, Munro MG. Incisional hernia following laparoscopy: a survey of the American Association of Gynecologic Laparoscopists. *Obstet Gynecol* 1994 Nov;84(5):881–4.
- Duepre HJ, Senagore AJ, Delaney CP, Fazio VW. Does means of access affect the incidence of small bowel obstruction and ventral hernia after bowel resection? Laparoscopy versus laparotomy. *J Am Coll Surg* 2003 Aug;197(2):177–81.
- McGee MF, Rosen MJ, Marks J, et al. A primer on natural orifice transluminal endoscopic surgery: building a new paradigm. *Surg Innov* 2006 Jun;13(2):86–93.
- Ridwelski K, Pross M, Schubert S, et al. Combined endoscopic intragastral resection of a posterior stromal gastric tumor using an original technique. *Surg Endosc* 2002 Mar;16(3):537.
- Hu B, Chung SCS, Sun LC, et al. Endoscopic suturing without extracorporeal knots: a laboratory study. *Gastrointest Endosc* 2005 Aug;62(2):230–3.
- Sclabas GM, Swain P, Swanström LL. Endoluminal methods for gastrotomy closure in natural orifice transenteric surgery (NOTES). *Surg Innov* 2006 Mar;13(1):23–30.