

# Advances in Imaging—The Changing Environment for the Imaging Specialist

By John Rego, MD  
KM Tan, MD

**CT scanners are now capable of obtaining 128 slices in less than one second.**

Over the last two to three decades, the demand for imaging services has blossomed at an unprecedented rate. New modalities have either been introduced as in magnetic resonance imaging (MRI) and positron emission tomography (PET) or significantly improved as in computed tomography (CT) and ultrasound (US).

The increasing sophistication of cross-sectional imaging with very rapid development and integration of interventional radiology into the clinical arena has had a dramatic impact on patient care. The imaging specialist now faces a remarkable transition in his/her work environment.

Bryan refers to two separate but related phenomena.<sup>1</sup> The marked increase in information available from modality advances, and now available in three dimensions, accompanied by technology allowing extensive digital manipulation of such data presages a new era in medical imaging.


Digital data and technology have revolutionized the imaging field. The electronic acquisition, interpretation, transmission and storage of image data has not only increased access for patients but also benefits their referring physicians. Imaging interpretations are available earlier and more readily, and there is almost instantaneous access to these examinations on their office computers. This, of course, mandates an integrated information enterprise that all Kaiser Permanente (KP) Regions have now or will have soon. Picture archiving and communications systems (PACS), radiology information systems (RIS), and hospital information systems (HIS) all contribute to seamless acquisition of image data through PACS, which, together with information from the RIS and the HIS, result in rapid interpretation available to clinicians together with the original images pulled from archival storage. Thus, images and reports are at the right place at the right time.

This technology has inevitably resulted in increasing efficiencies, particularly during off hours, allowing one

radiologist to offer interpretation coverage for 17 hospitals in Northern California. A similar situation prevails in Southern California (see page 47). It allows immediate access during the working day to subspecialty imaging expertise of multiple experts located throughout the Region and also allows the ability to provide interpretation services to some of the personnel-strapped Regions both within and outside of California.

Perhaps nowhere else in medicine has there been such rapid advance in technology than in CT scanning. With the advent of multidetector CT (MDCT) five years ago and, more recently volume CT (VCT), a relatively quiet revolution has taken place. CT scanners are now capable of obtaining 128 slices in less than one second. The entire chest, abdomen and pelvis can now be examined with submillimeter imaging in less than 15 seconds. This has led for the first time to true CT volume imaging where image reconstruction can take place in any plane with equal resolution.

We are just beginning to feel the impact of this very valuable tool in such areas as vascular imaging and virtual colonoscopy. The VCT has replaced peripheral



Radiologist Kurt Dibbern with a digital PACS setup for reading apropos.



**John Rego, MD**, (left) is Chair of the Northern California Chief Group. He is a member of the Northern California Medical Imaging Tech Committee and the National Imaging Core Group. E-mail: john.rego@kp.org.  
**KM Tan, MD**, (right) is Chief of Radiology at Kaiser Permanente in San Rafael California and is Chair of the National Imaging Core Group. He is a member of the Editorial Team for TPJ and has served in multiple state and national positions in CME, including the KP National CME Committee. E-mail: km.tan@kp.org.

diagnostic angiography in many centers and is poised to do the same for diagnostic coronary angiography. In the study of the colon, VCT has been shown to be superior to barium enema, approaching the sensitivity of colonoscopy in the detection of polyps larger than 9 mm.<sup>2</sup>

Advances in software have allowed almost instantaneous display of the images in shaded 3-D representations. This is proving invaluable in preoperative planning. The addition of CT fluoroscopy has allowed rapid, accurate real-time placement of biopsy needles, drainage catheters, and therapy devices.

As the technology advances, several vendors plan to introduce scanners that will acquire up to 512 images per half second with coverage of 12 cm. This will allow for perfusion imaging where viability of tissue can be evaluated. Coronary arterial and myocardial viability will be able to be evaluated simultaneously. Beyond 512 imaging, scanners are being tested that will use large-area detectors that will allow examination of the entire abdomen in just one pass of the x-ray tube.

Advances in MRI are equally as remarkable. As the 1.5T technology matures, there is new technology in the form of 3T-field strength magnets that allow for faster, more detailed, and thinner imaging sections than its 1.5T counterpart. MRI is showing that it can compete with CT in noninvasive imaging of the heart. Multiplanar real-time images of the beating heart can now be obtained that allow for full, functional assessment of the heart. With contrast, perfusion studies can also be obtained.

MRI remains the imaging examination of choice for musculoskeletal and neurologic applications and will continue to compete with CT in evaluation of the vascular tree. And many new applications of MRI will spur further growth. For example, in the breast, with the use of gadolinium contrast agents, MRI is proving to be very sensitive for detection of small breast cancers. Its role in this regard is still being evaluated. When coupled with focused high-energy ultrasound, MRI can be used to guide noninvasive tumor therapies. It has shown its usefulness in treating such tumors and uterine fibroids and in limited applications of other visceral tumors.

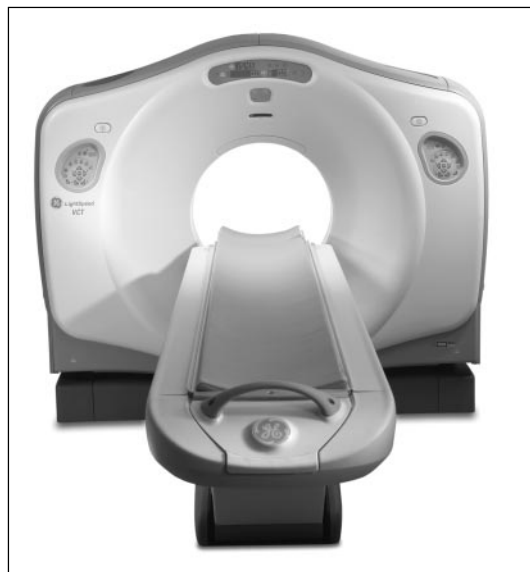Spurred on by miniaturization and by advances in computing power, the applications of ultrasound continue to grow. It is now possible to do high-quality ultrasound on devices the size of a laptop computer. Some devices in development are no larger than a PDA; these may indeed be the stethoscopes of the future. Three- and 4-D ultrasound have been further refined and are now being used in fetal imaging and ultrasound contrast imaging. Voice recognition and real-time image opti-

mization (tuning of the image to the patient's own acoustic properties) have improved patient workflow. With the pending approval of ultrasound contrast agents, ultrasound will compete with CT and MRI in the evaluation of the liver.

Interventional radiology continues to grow as procedures migrate from the OR to the IR suite. Stents and stent grafts have dramatically changed the practice of vascular surgery. Vascular surgeons and interventional radiologists have joined forces in many labs with a merging of their two specialties. Percutaneous tumor ablation, stabilization of vertebral body fractures, tumor embolization, venous ablation and recanalization are all procedures now common to the interventional labs.

New flat panel detectors have improved image quality and decreased radiation dose. New rotation angiographic techniques have allowed 3-D vascular image displays. With tube rotation it is now possible through post processing to obtain multislice CT images from the IR equipment.

Digital image acquisition has replaced film throughout the Radiology Department. Digital detectors are now used instead of film to allow immediate image review. This advance has led to an increase in image quality and a 50% decrease in imaging time. Dual-energy subtraction has allowed improved evaluation of the lungs by subtraction of the bony structures. Additional application of computer-aided diagnosis (CAD) has led to a 10% increase in tumor detection in



64 slice CT scanner now used for cardiac work.

**Digital detectors are now used instead of film to allow immediate image review. This advance has led to an increase in image quality and a 50% decrease in imaging time.**

the chest and breast. This same application is being trialed in CT colonoscopy as well.

Thus several trends are becoming clearer. The earlier and more frequent use of imaging will continue with a shortening of the initial clinical evaluation. As indicated above, the 64-slice CT scanner will allow immediate evaluation of a patient's chest pain, allowing differentiation between a benign situation and the possibility of a heart attack, an aneurysm, or a pulmonary embolism.

Technology will continue to drive care from the hospital. Decreasing cost and size of equipment will allow CT and MRI to devolve outside the hospital Radiology Department into freestanding situations.

The readily available image distribution process ironically will decrease reliance on the radiologist and there will be an enhanced shift to proactive, prophylactic screening in imaging. Computer-assisted detection and diagnosis in the areas of breast, lung, and colon disease are but a harbinger of such use in all clinical areas. Last but not least, functional and metabolic imaging is becoming a reality, and the promise of genetic and molecular marker imaging is not far behind.

One issue merits ongoing discussion and research. Advances in technology serve as one of the most important drivers of health care spending growth. Currently in the United States, medical care consumes more than 14% of the gross domestic product and is likely to reach 17.7% by 2012.<sup>3</sup>

Increases in the supply of specific technologies such as CT and MRI are associated with higher numbers of procedures per population and with consequent higher health care spending. Experience has shown that co-existence of CT and MRI is not complementary but supplementary. Thus, MRI availability does not offset CT use.<sup>4</sup>

While there may be a legitimate argument for bypassing the current progression of imaging tests from the least expensive to more costly examinations in favor of expensive high-tech imaging as a first-time test that provides more information, the effect is a distinct overall increase in health care spending. With the number of uninsured Americans approaching 50 million and with more of us unable to afford soaring health care costs, it is appropriate to question to what extent we can and should continue to spend dollars in pursuit of increasing diagnostic capabilities that in turn increase the probability of detecting multiple benign abnormalities and the consequent need to resolve them. Can we afford an "arms race" among manufacturers as they continue to outdo one another in the increasing detail and sophistication of their imaging devices? Is it appropriate to tolerate surging health care costs, especially in view of the lack of well-planned cost effectiveness and outcomes studies to support the increasing use of such modalities? ❖

#### References

1. Bryan RN. The digital rEvolution: the millennial change in medical imaging. *Radiology* 2003 Nov;229(2):299-304.
2. Pickhardt PJ, Choi JR, Hwang I, et al. Computed tomographic virtual colonoscopy to screen for colorectal neoplasia in asymptomatic adults. *N Engl J Med* 2003 Dec 4;349(23):2191-200. Epub 2003 Dec 1.
3. Gazelle GS, McMahon PM, Siebert U, Beinfeld MT. Cost-effectiveness analysis in the assessment of diagnostic imaging technologies. *Radiology* 2005 May;235(2):361-70.
4. Baker L, Birnbaum H, Geppert J, Mishol D, Moynour E. The relationship between technology availability and health care spending. *Health Aff (Millwood)* 2003 Jul-Dec; Suppl Web Exclusives:W3-537-51.

## Inventions

Our inventions mirror our secret wishes.

—Mountolive, *Lawrence Durrell, 1912-1990, Anglo-Irish novelist and playwright*