

Hyperthyroid-Induced Cardiomyopathy in an Adolescent

Peter N Mattar, MD, MPH
Eugene Y Hwang, MD

Introduction

Although there is ample evidence of hyperthyroidism associated with heart failure in adults,¹⁻³ few reports exist in the medical literature regarding children who experience thyrotoxic cardiomyopathy. In this report we describe an adolescent patient who presented for urgent care with vague symptoms of palpitations, headaches, lower-extremity swelling, and dyspnea on exertion and was found to have congestive heart failure (CHF) secondary to hyperthyroidism.

Case Example

A previously healthy African-American girl, aged 11 years, presented for urgent care with a three-week history of exercise and heat intolerance, dyspnea on exertion, chest pain, and a four-day history of lower-extremity edema and headaches. In addition, she reported feeling fatigue and nervousness and having periods of insomnia. She also complained of intermittent feelings of racing heartbeat and palpitations during the preceding three weeks that sometimes lasted an entire day. She reported no history of fevers, sore throat, rash, weight loss, or diarrhea. The patient experienced menarche at age 11 years 6 months and had not had any subsequent menses. She had no history of syncope and reported being able

to sleep flat on her back without problems. According to her mother, she had a long history of tachycardia. Her mother said that one year earlier while undergoing a routine physical examination, the girl had a heart rate of >130 beats/min. The patient's family history was negative for congenital heart disease, cardiomyopathy, or sudden unexplained death. The girl's maternal aunt had been found to have supraventricular tachycardia at age 38 years.

Initial vital signs included a heart rate of 130 beats/minute and respiratory rate of 22 breaths/minute. The patient was thin but not cachectic. Her skin was warm and moist, she was in no distress, and she had neither lymphadenopathy nor a neck mass. She did exhibit mild bilateral hand trembling, but she showed no evidence of hair loss. Her thyroid gland was enlarged, measuring 5 cm, and was soft and without nodules. A cardiac examination revealed a slightly hyperactive precordium, a gallop rhythm, and a 2/6 systolic murmur at the left lower sternal border and apex. The patient did not exhibit lid lag, periorbital edema, or pretibial myxedema. An electrocardiogram (Figure 1) showed sinus tachycardia, right atrial enlargement, and left ventricular hypertrophy. Chest radiographs revealed mild cardiomegaly with a normal pulmonary

vascular pattern. The echocardiogram showed moderate mitral and tricuspid regurgitation with moderate left heart enlargement. The patient was admitted to the hospital and given 20 mg of furosemide intravenously twice a day and 2.5 mg of lisinopril every day for CHF.

The patient then had a significant decrease in her lower-extremity edema. An assessment of thyroid-stimulating hormone (TSH) level was ordered at the initial urgent care visit; she had a TSH level of <0.01 μ U/mL. Her level of free thyroxine (T_4) was 3.70 μ /dL. Because of her hyperthyroidism, the patient was instructed to begin taking 15 mg of methimazole per day and 50 mg of atenolol twice a day. The patient was discharged after three days of hospitalization.

At the two-month follow-up examination, she had decreased fatigue, insomnia, and palpitations. Her heart rate had decreased to 110 beats/min. After four months, the patient reported a 12-pound weight gain within the preceding three months, had complete resolution of fatigue and insomnia, and had a heart rate of 92 beats/min. She also reported no further dyspnea on exertion, shortness of breath, palpitations, or heat intolerance. A cardiac echocardiogram obtained five months after initial assessment showed decreased tricuspid regurgi-

Peter N Mattar, MD, MPH, (left) is a Resident in the Family Medicine Department at the Fontana Medical Center in Fontana, CA. E-mail: pmattar@yahoo.com.

Eugene Y Hwang, MD, (right) is an Attending Physician in the Department of Pediatric Cardiology at the Fontana Medical Center in Fontana, CA. E-mail: eugene.y.hwang@kp.org.



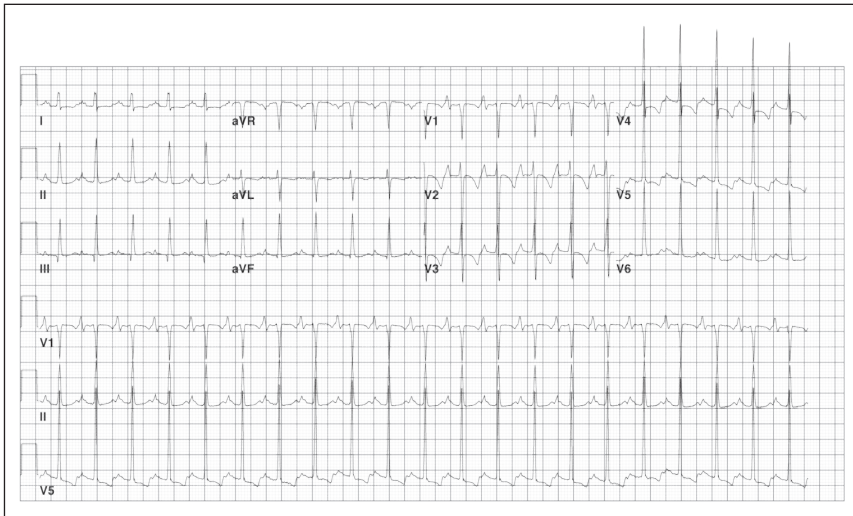


Figure 1. The initial electrocardiogram taken at baseline on presentation in the Pediatric Urgent Care Clinic.

tation with right ventricular systolic pressure of 45 mm Hg versus the initial 54 mm Hg. At that time, her TSH level was 4 μ U/mL and her free T_4 level was 1.47 μ /dL.

Discussion

Cardiovascular manifestations of hyperthyroidism are common and include arrhythmias,^{1,4-9} such as sinus tachycardia, atrial fibrillation, and atrial flutter.¹⁰ CHF and cardiomyopathy as a result of hyperthyroidism are not common, especially in children. It is not known whether cardiomyopathy in hyperthyroidism is secondary to direct toxic effects of excess thyroid hormone, whether it results from the hyperdynamic or high-output stress caused by the thyroid hormone, or whether it is caused by a combination of both.¹¹ However, cardiomyopathy caused by hyperthyroidism has been shown to be reversible in adults with antithyroid therapy.¹²⁻¹⁴ Although it is rare for hyperthyroidism to present as CHF or cardiomyopathy, it should be considered in the differential diagnosis, as it is reversible.

The case we describe here illustrates how early diagnosis of underlying hyperthyroidism in a child can accelerate the healing process in cardiac disease. Thyrotoxic cardiomyopathy in children has been reported in very few publications,¹⁵ but immediate antithyroid therapy has been shown to provide good long-term outcome in these patients. The increasing incidence of childhood thyrotoxicosis^{15,16} and the possible reversal of cardiomyopathy in these young patients with therapy emphasize the importance of early detection and management of hyperthyroidism. ❖

Disclosure Statement

The author(s) have no conflicts of interest to disclose.

Acknowledgment

Katharine O'Moore-Klopf of KOK Edit provided editorial assistance.

References

- Polikar R, Burger AG, Scherrer U, Nicod P. The thyroid and the heart. *Circulation* 1993 May;87(5):1435-41.
- Shirani J, Barron MM, Pierre-Louis ML, Roberts WC. Congestive heart failure, dilated cardiac ventricles, and

- sudden death in hyperthyroidism. *Am J Cardiol* 1993 Aug 1;72(3):365-8.
- Klein I. Thyroid hormone and the cardiovascular system. *Am J Med* 1990 Jun;88(6):631-7.
- Woeber KA. Thyrotoxicosis and the heart. *N Engl J Med* 1992 Jul 9;327(2):94-8.
- Woeber KA. Thyrotoxicosis and cardiac disease. *Heart Dis Stroke* 1993 Sep-Oct;2:415-7.
- Gomberg-Maitland M, Frishman WH. Thyroid hormone and cardiovascular disease. *Am Heart J* 1998 Feb;135(2 Pt 1):187-96.
- Kahaly GJ, Nieswandt J, Mohr-Kahaly S. Cardiac risks of hyperthyroidism in the elderly. *Thyroid* 1998 Dec;8(12):1165-9.
- Toft AD, Boon NA. Thyroid disease and the heart. *Heart* 2000 Oct;84(4):455-60.
- Klein I, Ojamaa K. Thyroid hormone and the cardiovascular system. *N Engl J Med* 2001 Feb;344(7):501-9.
- Roffi M, Cattaneo F, Topol EJ. Thyrotoxicosis and the cardiovascular system: subtle but serious effects. *Cleve Clin J Med* 2003 Jan;70(1):57-63.
- Vydt T, Verhelst J, De Keulenaer G. Cardiomyopathy and thyrotoxicosis: tachycardiomyopathy or thyrotoxic cardiomyopathy? *Acta Cardiol* 2006 Feb;61(1):115-7.
- Khandwala HM. A case of congestive heart failure due to reversible dilated cardiomyopathy caused by hyperthyroidism. *South Med J* 2004 Oct;97(10):1001-3.
- Markowitz C, Yates WM. Response of explanted cardiac muscle to thyroxine. *Am J Physiol* 1932;100:162-6.
- Forfar JC, Muir AL, Sawers SA, et al. Abnormal left ventricular function in hyperthyroidism: evidence for a possible reversible cardiomyopathy. *N Engl J Med* 1982 Nov 4;307(19):1165-70.
- Cavallo A, Casta A, Fawcett HD, Nusynowitz ML, Wolf WJ. Is there a thyrotoxic cardiomyopathy in children? *J Pediatr* 1985 Oct;107(4):531-6.
- Forssberg M, Arvidsson CG, Engvall J, Lindblad C, Snellman K, Aman J. Increasing incidence of childhood thyrotoxicosis in a population-based area of central Sweden. *Acta Paediatr* 2004 Jan;93(1):25-9.